

Effect of Delayed Scanning and Scanning Resolution Using Photostimulable Phosphor Plates on Detection of Vertical Root Fracture: *In Vitro* Study

Photostimüle Edilebilir Fosfor Plakalar Kullanılarak Gecikmiş Tarama ve Tarama Çözünürlüğünün Dikey Kök Kırıklarının Tespitine Etkisi: *İn Vitro* Çalışma

Elifhan ALAGÖZ^a, Tuğba ÜNVER^b, Ayşegül YABACI TAK^c, Şerife ÖZDEMİR^d

^aDepartment of Oral and Maxillofacial Radiology, Bezmîalem Vakıf University Faculty of Dentistry, İstanbul, Türkiye

^bDepartment of Oral and Maxillofacial Radiology, İstanbul Galata University Faculty of Dentistry, İstanbul, Türkiye

^cDepartment of Biostatistics, Bezmîalem Vakıf University Faculty of Medicine, İstanbul, Türkiye

^dDepartment of Pedodontics, Bezmîalem Vakıf University Faculty of Dentistry, İstanbul, Türkiye

ABSTRACT Objective: Detecting vertical root fractures (VRFs) can be challenging in dentistry due to their subtle and often concealed nature. This study aimed to assess the impact of varying resolutions and delayed scanning times of photostimulable phosphor plates on the diagnosis of VRFs. Can different resolutions and/or delayed scan times enhance the diagnosis of VRFs? **Material and Methods:** In this *in vitro* study, forty extracted single-rooted premolar teeth were utilized. The crowns of all teeth were removed, and root canals were prepared. The teeth were divided into 2 groups: 20 study teeth with VRFs and 20 teeth without VRFs. VRFs were created using an Instron machine. All tooth roots were positioned in the premolar region of a dry human mandible and fixed with wax. Subsequently, periapical radiographs were taken using a parallel technique. Radiographs were scanned at 4 different times post-exposure: immediately, 30 minutes later, 2 hours later, and 4 hours later, and at three different resolutions: high speed, high resolution, and super high resolution. Statistical analyses were conducted using IBM SPSS statistics 26.0. **Results:** Intra- and interobserver agreement exhibited substantial to almost perfect ranges of agreement. Statistically significant differences were not observed in the diagnosis of VRFs when comparing different resolutions and scanning times. **Conclusion:** Varying resolutions and/or delayed scan times did not improve the diagnosis of VRFs. In clinical practice, a comprehensive detection of VRFs might necessitate a combination of different imaging techniques, immediately scanning, optimizing resolution settings, and clinical assessment.

ÖZET Amaç: Diş hekimliğinde, dikey kök kırıklarının (DKK) teşhisi, kırıkların belirgin olmayan ve genellikle net olarak görüntülenemeyen niteliklerinden dolayı zor olabilir. Bu çalışma, fotostimüle edilebilir plakaların farklı çözünürlüklerinin ve gecikmeli tarama zamanlarının DKK'lerin teşhisi üzerindeki etkisini değerlendirmeyi amaçlamaktadır. Farklı çözünürlükler ve/veya gecikmeli tarama zamanları, DKK'lerin teşhisini kolaylaştırabilir mi? **Gereç ve Yöntemler:** Bu *in vitro* çalışmada, 40 çekilmiş tek köklü premolar diş kullanıldı. Tüm dişlerin kronları miniselement sınırından kesilerek, uzaklaştırıldı ve kök kanal preparasyonları yapıldı. Dişler, 20 DKK'li çalışma grubu ve 20 DKK'siz kontrol grubu olmak üzere 2 gruba ayrıldı. DKK'leri, bir Instron makinesi kullanılarak oluşturuldu. Tüm diş kökleri, kuru bir insan mandibulasının premolar bölgesine yerleştirildi, mum ile sabitlendi. Ardından, paralel teknik kullanılarak periapikal radyograflar çekildi. Radyograflar, ışınlamadan hemen sonra, 30 dk sonra, 2 saat sonra ve 4 saat sonra olmak üzere 4 farklı zaman diliminde ve yüksek hız, yüksek çözünürlük ve süper yüksek çözünürlük olmak üzere 3 farklı çözünürlükte tarandı. İstatistiksel analizler IBM SPSS statistics 26.0 kullanılarak gerçekleştirildi. **Bulgular:** Gözlemci içi uyum, önemli derecede yüksek; gözlemciler arası uyum neredeyse mükemmel olarak gözlemlendi. Farklı çözünürlüklerde ve farklı tarama zamanlarında, DKK teşhisinde istatistiksel olarak anlamlı farklılıklar gözlemlenmedi. **Sonuç:** Farklı çözünürlükler ve/veya gecikmeli tarama zamanları, DKK'lerin teşhisini iyileştirmedi. Klinik uygulamada, DKK'lerin kapsamlı bir şekilde teşhisi, farklı görüntüleme tekniklerinin kombinasyonunu, ışınlamadan hemen sonra taramayı, çözünürlük ayarlarını optimize etmeyi ve klinik değerlendirmeyi gerektirebilir.

Keywords: Diagnostic imaging; root canal preparation; *in vitro* study

Anahtar Kelimeler: Tanısal görüntüleme; kök kanalı şekillendirmesi; *in vitro* çalışma

TO CITE THIS ARTICLE:

Alagöz E, Ünver T, Yabancı Tak A, Özdemir Ş. Effect of delayed scanning and scanning resolution using photostimulable phosphor plates on detection of vertical root fracture: *In vitro* study. Türkiye Klinikleri J Dental Sci. 2024;30(1):31-9.

Correspondence: Elifhan ALAGÖZ

Department of Oral and Maxillofacial Radiology, Bezmîalem Vakıf University Faculty of Dentistry, İstanbul, Türkiye

E-mail: elifhan.alagoz@bezmialem.edu.tr



Peer review under responsibility of Türkiye Klinikleri Journal of Dental Sciences.

Received: 13 Oct 2023

Received in revised form: 22 Dec 2023

Accepted: 25 Dec 2023

Available online: 29 Dec 2023

2146-8966 / Copyright © 2024 by Türkiye Klinikleri. This is an open access article under the CC BY-NC-ND license (<http://creativecommons.org/licenses/by-nc-nd/4.0/>).

Detecting vertical root fractures (VRFs) in dentistry can be challenging due to their subtle and often concealed nature. According to the American Association of Endodontists, a VRF is a fracture that runs longitudinally along the root, originating from the apex and extending towards the crown.¹ It is imperative to differentiate VRFs from other clinical conditions with similar symptoms.^{2,3} Clinical scenarios involving VRFs may mimic periodontal diseases or failed root canal treatments.¹ Often, a combination of symptoms, including pain, local swelling, tooth mobility, periodontal pockets, sinus tracts, abscesses, sensitivity, pain upon percussion and palpation, and radiographic findings such as radiolucent halos, irregular or angular bone loss along the root surface, are indicative of VRFs.⁴ The presence of one or more sinus formations, along with radiographic halos or J-shaped radiolucent areas around the root fracture, is pathognomonic for VRFs.² Early detection of VRFs poses a challenge for oral and maxillofacial radiology and endodontology, especially when there are no clinical or radiographic symptoms.⁴

Photostimulable phosphor (PSP) plates represent a digital imaging technology employed in dentistry. These plates resemble traditional X-ray films but can be used repeatedly, which makes them environmentally friendly and cost-efficient.⁵ When exposed to X-rays, PSP plates store energy and can be subsequently “scanned” to produce digital images.

The term “delayed scanning” refers to the time gap between exposing the PSP plate to X-rays and the actual scanning process. Research has explored the impact of delayed scanning on image quality and diagnostic accuracy.⁵⁻⁷ It is generally observed that immediate scanning post X-ray exposure yields the best image quality and diagnostic outcomes. Between exposure and scanning, there is a risk of image degradation, potentially leading to reduced visibility of fine details like root fractures.

The scanning resolution is pivotal in detecting VRFs. Recommendations often suggest that radiographs with higher spatial resolutions are more effective in revealing radiographic details.⁸ Higher resolutions enable the identification of fracture lines, thereby enhancing diagnostic accuracy. Lower scan-

ning resolutions might not capture the requisite level of detail, possibly resulting in overlooked or misinterpreted fractures.

In the assessment of root fractures, periapical radiography is typically the initial imaging technique due to its high spatial resolution, cost-effectiveness, and simplicity.^{4,9} However, the superimposition of images in two-dimensional radiographs can limit fracture line visualization, occasionally necessitating three-dimensional (3D) evaluations.¹⁰⁻¹² Modern dental imaging includes modalities like cone beam computed tomography (CBCT) for detecting VRFs due to their superior spatial resolution and 3D imaging capabilities.¹⁰⁻¹² CBCT offers highly detailed cross-sectional images, proving effective in diagnosing VRFs even in complex cases. Nevertheless, the associated radiation dose must be considered when using CBCT, as it delivers a higher radiation dose compared to conventional X-rays or PSP plates.

This study aims to assess the impact of different scanning resolutions and delayed scanning times of PSP plates on the diagnosis of VRFs.

MATERIAL AND METHODS

This *in vitro* study was conducted after obtaining approval from the Ethics Committee of Bezmiâlem Vakıf University, with an approval document number of 2779 in February, 21 2018. All procedures strictly adhere to the principles outlined in the Declaration of Helsinki. Forty extracted single-rooted premolar teeth were utilized. Initially, all teeth underwent clinical and radiological examination. Teeth that had undergone endodontic treatment, exhibited internal-external root resorption, had supernumerary roots or canals, featured obliterated root canals, or displayed calcified pulp were excluded. Teeth with existing root fractures were also excluded.

The external surfaces of all tooth roots were meticulously cleaned with a toothbrush to ensure no enamel-cement fracture lines were overlooked. The crowns of all teeth were removed at the cement-enamel junction using a diamond disc. Root canals were shaped using a rotating Ni-Ti Rotary system at 350 rpm and 1N force, with constant irrigation using distilled water.

The teeth were divided into two groups: a study group consisting of 20 teeth with VRF, and a control group consisting of 20 teeth without VRF. To simulate VRF, twenty tooth roots were individually placed inside silicone tubes measuring 25 mm in length and 10 mm in diameter (Figure 1). The creation of VRF was achieved using a Universal Test Machine (Instron, Shimadzu, Japan) (Figure 2).

Guide grooves were prepared along the enamel-cement junction line of the 20 teeth in the study group. An angled metal tip was then inserted into these guide grooves. Program settings and calibrations were established, and the test was initiated by programming a displacement rate of 1 mm per minute with a load of 500 Newtons. The machine halted automatically upon fracture occurrence.

The tooth roots were positioned within the premolar area of a dry human mandible skull. Thin pink wax was used to secure the periphery of all tooth roots within their sockets.

All digital periapical radiographs were captured using an X-ray machine (Belmont PHOT-X II, Japan) and PSP (Carestream CS 7600, Japan). The PSPs were securely positioned within a standard periapical radiograph film holder. Radiographs were taken with an X-ray apparatus (Belmont PHOT-X II, Japan) set at 60kV, 7mA, and 0.2 s exposure time, with a source-to-object distance of 30 cm. The radiographic procedure utilized the parallel technique and a film holder (Figure 3).

For the study group, PSPs were scanned using a scanner at 4 different time points (t1: immediately

after exposure, t2: 30 minutes after exposure, t3: 2 hours after exposure, t4: 4 hours after exposure), each at three different resolutions (high speed, high resolution, super high resolution) (Figure 4). At each scanning time, PSPs were imaged at three different resolutions by sequentially selecting the options “high speed,” “high resolution,” and “super high resolution” from the “default scan resolution” tab in the Carestream CS 7600 software program. In contrast, the control group’s PSPs were scanned once (t1: immediately after exposure), also at three different resolutions (high speed, high resolution, super high resolution) (Figure 5).

A total of 300 images were captured for assessment (20 teeth x 3 different resolutions x 4 different scanning times for the study group + 20 teeth x 3 different resolutions x 1 scanning time for the control group).

Subsequently, all images underwent evaluation by both an experienced oral and maxillofacial radiologist and a skilled pedodontist, independently. The assessment aimed to determine the presence or absence of VRF and was scored using a five-point scale as outlined below:

1. No evidence of root fracture
2. Likely no evidence of root fracture
3. Uncertain
4. Likely presence of root fracture
5. Definite presence of root fracture



FIGURE 1: Teeth placed within silicone.




FIGURE 2: Instron machine.

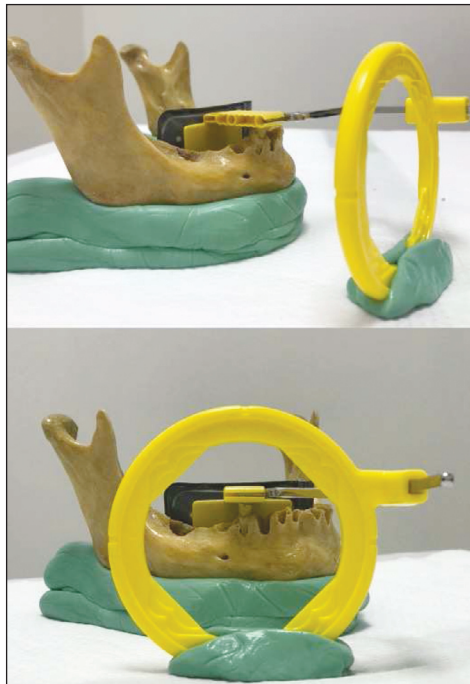


FIGURE 3: Photograph illustrating the image acquisition process.

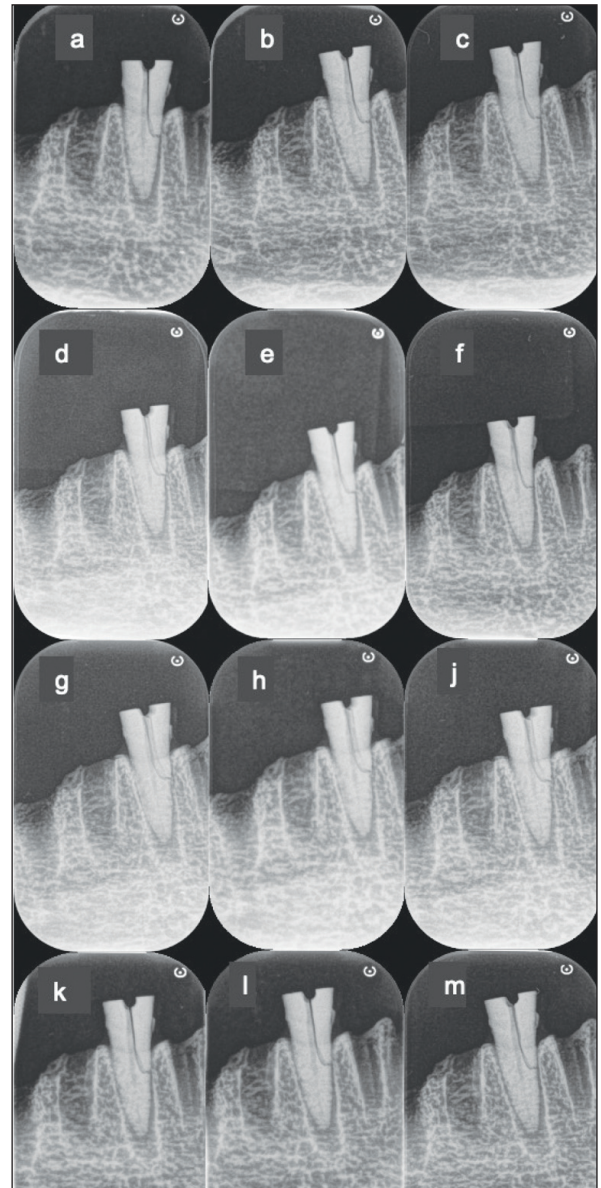


FIGURE 4: Study group (a: high speed, b: high resolution, c: super high resolution-immediately); (d: high speed, e: high resolution, f: super high resolution-30 minutes); (g: high speed, h: high resolution, j: super high resolution-2 hours); (k: high speed, l: high resolution, m: super high resolution-4 hours after exposure).

Following a 30-day interval, a quarter of the sample was reevaluated to gauge intra-observer reproducibility.

STATISTICAL ANALYSIS

The distribution of the data underwent analysis using the Shapiro-Wilk test. To compare three or more independent groups lacking a normal distribution, the

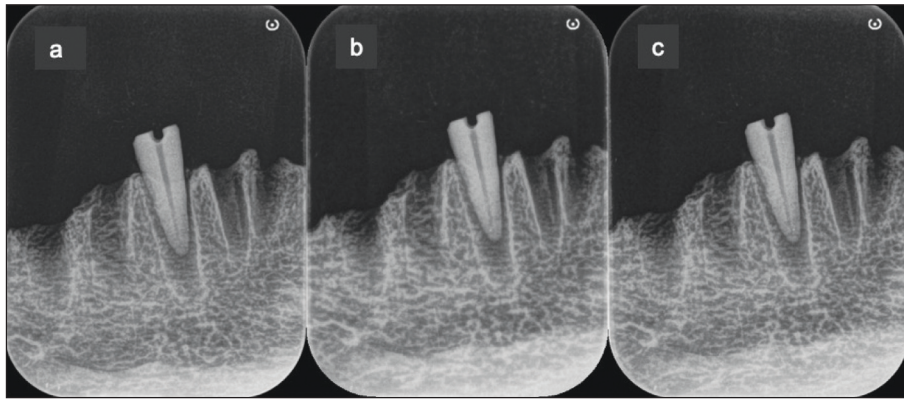


FIGURE 5: Control group (a: high speed-immediately, b: high resolution-immediately, c: super high resolution-immediately).

Kruskal-Wallis test was employed. The interclass correlation coefficient (ICC) was calculated to assess agreement among and within observers. Furthermore, the Wilcoxon test was utilized to assess disparities in measurements, determining intra-observer reliability.

For the evaluation of time, resolution, and time-resolution interactions, a two-way analysis of variance test was implemented. Receiver operating characteristic (ROC) analysis was conducted to derive area under the curve, sensitivity, specificity, and accuracy values. The ROC analysis was carried out using the MedCalc 12.3 (MedCalc software bvba, Belgium) program.

Descriptive statistics for the data were presented as either mean±standard deviation or median (minimum-maximum) values. All additional statistical analyses were executed using IBM SPSS Statistics 26.0 (USA), with a significance level set at $\alpha=0.05$.

POWER ANALYSES

Based on the findings derived from the study, with an ICC coefficient of 0.584, the study's statistical power was determined to be 80%. This determination was made with a sample size of $n=40$, operating at a 95% confidence level and a significance level of 0.05.

RESULTS

The level of agreement among observers in both the study and control groups was assessed and presented in Table 1. The outcomes revealed that within the study group, the agreement coefficient among ob-

TABLE 1: Assessment of inter-observer agreement using the ICC coefficient.

Group	ICC	p value*	95% CI
Study group	0.789	<0.001	0.728-0.838
Control group	0.590	<0.001	0.308-0.757
Total	0.932	<0.001	0.914-0.945

*It is the p value of the ICC coefficient; CI: Confidence interval; ICC: Interclass correlation coefficient.

servers was calculated as 0.789, indicating a substantial degree of agreement ($p<0.001$).¹³ Combining the observations from both the study and control groups, the agreement coefficient among observers was calculated as 0.932 ($p<0.001$), denoting an almost perfect level of agreement (Table 1).¹³

The reliability of the observers in detecting VRF was assessed and presented in Table 2. Upon evaluating the discrepancies among the observers, no statistically significant differences were observed ($p>0.05$). Intra-observer agreement varied from substantial to almost perfect, ranging from 0.666 to 0.903 (Table 2).¹³

Following the analysis conducted to assess the detection of VRF from images acquired at 4 different time points and three different resolutions within the study group, it was found that the interaction among time, resolution, and time*resolution did not yield a statistically significant difference ($p>0.05$). The outcomes from the immediate scan and subsequent delayed scan times after X-ray exposure exhibited similarity (Table 3)

TABLE 2: Intra-observer agreement.

	Immediately	1 month later	p value**	ICC	p value***
Observer 1	4.01±1.52	3.51±1.71	0.670	0.666	<0.001
Observer 2	4.04±1.55	3.91±1.62	0.070	0.903	<0.001

p values are from the paired sample t-test; *It is the p value of the ICC coefficient; ICC: Intraclass correlation coefficient.

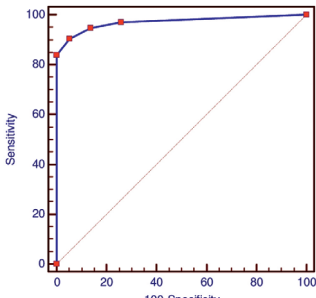
TABLE 3: Assessment of varied scan times and resolutions.

Resolution	Scan time	$\bar{X}\pm SD$	p value _{resolution}	p value _{scan time}	p value _{resolution*scantime}
High speed	Immediately	4.66±0.18	0.518	0.720	0.888
	30 min later	4.70±0.19			
	2 h later	4.40±0.19			
	4 h later	4.55±0.19			
High resolution	Immediately	4.61±0.18			
	30 min later	4.50±0.19			
	2 h later	4.45±0.19			
	4 h later	4.75±0.19			
Super high resolution	Immediately	4.70±0.19			
	30 min later	4.60±0.19			
	2 h later	4.75±0.19			
	4 h later	4.80±0.19			

The p values are the p values from the two way analysis of variance test. Data are expressed as $\bar{X}\pm SD$; SD: Standard deviation.

TABLE 4: ROC analysis.

Criterion	Sensitivity	95% CI	Specificity	95% CI	AUC	p value
>3	90.50	86.1-93.9	94.83	85.6-98.9	0.971	<0.001



ROC: Receiver operating characteristic; CI: Confidence interval; AUC: Area under the curve.

A statistically significant difference exists in the discriminative capacity between the study and control groups. The test exhibited a sensitivity of 90.50% and a specificity of 94.83%. These sensitivity and specificity values are deemed satisfactory for discrimination purposes (Table 4).

DISCUSSION

This study sought to assess the impact of varying scanning resolutions-specifically, high speed, high resolution, and super high resolution-alongside different post-exposure scanning times (immediately, 30

minutes, 2 hours, and 4 hours later) on the detection of VRFs using periapical radiography. The findings indicated that there were no statistically significant differences in the ability to diagnose VRFs when comparing different resolutions and scanning times

Patel et al. investigated the detection of VRFs in root-filled teeth through periapical radiographs and CBCT scans.² In their study, Patel et al. concluded that periapical radiographs exhibit higher overall specificity than CBCT.² Furthermore, the detection rates for complete and incomplete VRFs were greater with periapical radiographs compared to CBCT. Similarly, Ezzodini Ardakani et al. found that the specificity of periapical radiography in detecting VRFs was superior in their research assessing the diagnostic efficacy of CBCT and periapical radiography for VRF detection.¹⁴ However, Valiozadeh et al. reported in their study on the accuracy of conventional radiography, digital radiography, and CBCT in detecting VRFs in single-rooted teeth that CBCT outperformed both conventional and digital radiography.¹⁵ Moreover, Varshosaz et al. observed in their study comparing conventional radiography with CBCT for VRF detection that CBCT demonstrated higher accuracy.¹⁶

Taking into account Patel et al. findings along with those of Ezzodini Ardakani et al., and considering the advantages of periapical radiographs over CBCT, such as lower cost, easier accessibility, and reduced radiation exposure, the present study employed periapical radiographs.^{2,14}

Wenzel et al. conducted an assessment of transverse root fractures using an *in vitro* model, comparing variable-resolution CBCT with enhancement filtration against intraoral PSP radiography.¹⁷ Their study revealed that there was no statistically significant distinction between low-resolution CBCT and PSP images. However, original high-resolution CBCT images exhibited higher sensitivity compared to both low-resolution images and PSP images. In another study, Wenzel et al. evaluated the efficacy of high-resolution charge-coupled device sensors versus medium-resolution PSP digital receptors for detecting root fractures in an *in vitro* setting.¹⁸ The results indicated that radiovisiography-*ui*TM images achieved higher sensitivities than Digora® (Soredex,

Helsinki, Finland) PSP images ($p < 0.05$). Nonetheless, no statistically significant difference in specificities was noted between the two digital systems.

De Martin E Silva D et al. explored the impact of filtering on CBCT images with different resolutions for diagnosing VRFs in teeth with metallic posts.¹⁹ Their experimentation employed “sharpen” and “hard” filters, revealing that regardless of the presence of a metallic post, there was no significant difference between images obtained with filters and the original images.

Li et al. assessed proximal caries detection in storage phosphor plate radiographs scanned at 4 different resolutions: Digora FMX, Digora Optime High Resolution, Digora Optime Super Resolution (Digora Optime; Soredex/Orion Corp., Helsinki, Finland), Vistascan Standard Resolution (Dürr Dental GmbH, Bietigheim-Bissingen, Germany), and Vistascan Fine Resolution.⁸ They reported that radiographs scanned with Digora® Optime at both resolutions demonstrated superior proximal caries detection compared to the other resolutions.

Similar to the findings in De Martin E Silva D et al. study, current investigation concluded that the detection of VRFs from images obtained at 3 different resolutions did not exhibit statistically significant differences, and the evaluations yielded similar results.¹⁹

Sogur et al. investigated the impact of delayed scanning, involving immediate scanning as well as scans conducted at intervals of 10 minutes, 30 minutes, 60 minutes, and 120 minutes after exposure, on the detection of occlusal caries using storage phosphor plates.²⁰ Their findings revealed that values obtained from immediately scanned images exhibited higher detection rates compared to images scanned with different delays, and diagnostic accuracy decreased with increasing scan delays. Moreover, they noted no significant difference in the accuracy of caries detection between images scanned at 10 minutes vs. 30 minutes, 30 minutes vs. 60 minutes, and 30 minutes vs. 120 minutes delays.

Nascimento et al. reported that they did not observe significant differences in sensitivity, specificity, and accuracy among four different scans conducted immediately, at 30 minutes, 2 hours, and 4 hours after

exposure. However, the 4-hour delayed scan displayed lower values than the others.⁵ Similarly, Martins et al. found that objective analysis demonstrated a reduction in pixel density after 4 hours for all storage combinations, while subjectively, this density loss was not statistically significant.⁷

Akdeniz et al. explored the impact of delayed scanning of storage phosphor plates, conducting scans immediately, at 10 minutes, 30 minutes, 60 minutes, and 24 hours after exposure.⁶ Consistent with other studies, Akdeniz et al. reported that mean gray values increased with scan delay.⁶ In line with the existing literature, this study also found no statistically significant difference in the detection of VRFs among images obtained through scanning at 4 different times. Furthermore, it was concluded that image evaluations obtained by scanning immediately, at 30 minutes, 2 hours, and 4 hours after exposure were similar.

In current study, an aluminum wedge did not employ, which stands as a limitation. Furthermore, due to the *in vitro* design, the study was unable to include clinical assessments and was limited solely to single-rooted teeth. These considerations constitute the study's limitations.

CONCLUSION

In current study varying resolutions and/or delayed scan times did not improve the diagnosis of VRFs.

In clinical practice, a comprehensive detection of VRFs might necessitate a combination of different imaging techniques, and clinical assessment. In addition engaging with an oral and maxillofacial radiologist or endodontist and taking into consideration their expertise and clinical judgment can prove to be advantageous for achieving precise diagnosis.

Source of Finance

During this study, no financial or spiritual support was received neither from any pharmaceutical company that has a direct connection with the research subject, nor from a company that provides or produces medical instruments and materials which may negatively affect the evaluation process of this study.

Conflict of Interest

No conflicts of interest between the authors and / or family members of the scientific and medical committee members or members of the potential conflicts of interest, counseling, expertise, working conditions, share holding and similar situations in any firm.

Authorship Contributions

Idea/Concept: Tuğba Ünver, Elifhan Alagöz, Şerife Özdemir; **Design:** Tuğba Ünver, Elifhan Alagöz; **Control/Supervision:** Tuğba Ünver, Şerife Özdemir; **Data Collection and/or Processing:** Elifhan Alagöz, Ayşegül Yabancı Tak; **Analysis and/or Interpretation:** Elifhan Alagöz, Tuğba Ünver, Şerife Özdemir, Ayşegül Yabancı Tak; **Literature Review:** Elifhan Alagöz, Tuğba Ünver; **Writing the Article:** Elifhan Alagöz, Tuğba Ünver; **Critical Review:** Şerife Özdemir, Ayşegül Yabancı Tak, Tuğba Ünver.

REFERENCES

1. Khasnis SA, Kidiyoor KH, Patil AB, Kenganal SB. Vertical root fractures and their management. *J Conserv Dent.* 2014;17(2):103-10. [[Crossref](#)] [[PubMed](#)] [[PMC](#)]
2. Patel S, Brady E, Wilson R, Brown J, Mannocci F. The detection of vertical root fractures in root filled teeth with periapical radiographs and CBCT scans. *Int Endod J.* 2013;46(12):1140-52. [[Crossref](#)] [[PubMed](#)]
3. García-Guerrero C, Parra-Junco C, Quijano-Guaque S, Molano N, Pineda GA, Marin-Zuluaga DJ. Vertical root fractures in endodontically-treated teeth: A retrospective analysis of possible risk factors. *J Investig Clin Dent.* 2018;9(1). [[Crossref](#)] [[PubMed](#)]
4. Nascimento HA, Ramos AC, Neves FS, de-Azevedo-Vaz SL, Freitas DQ. The 'Sharpen' filter improves the radiographic detection of vertical root fractures. *Int Endod J.* 2015;48(5):428-34. [[Crossref](#)] [[PubMed](#)]
5. Nascimento HA, Visconti MA, Ferreira LM, Suarez MA, Haiter Neto F, Freitas DQ. Effect of delayed scanning on imaging and on the diagnostic accuracy of vertical root fractures in two photostimulable phosphor plates digital systems. *Int Endod J.* 2016;49(10):973-9. [[Crossref](#)] [[PubMed](#)]
6. Akdeniz BG, Gröndahl HG, Kose T. Effect of delayed scanning of storage phosphor plates. *Oral Surg Oral Med Oral Pathol Oral Radiol Endod.* 2005;99(5):603-7. [[Crossref](#)] [[PubMed](#)]
7. Martins MG, Whaites EJ, Ambrosano GM, Haiter Neto F. What happens if you delay scanning Digora phosphor storage plates (PSPs) for up to 4 hours? *Dentomaxillofac Radiol.* 2006;35(3):143-6. [[Crossref](#)] [[PubMed](#)]
8. Li G, Berkhout WE, Sanderink GC, Martins M, van der Stelt PF. Detection of in vitro proximal caries in storage phosphor plate radiographs scanned with different resolutions. *Dentomaxillofac Radiol.* 2008;37(6):325-9. [[Crossref](#)] [[PubMed](#)]
9. Junqueira RB, Verner FS, Campos CN, Devito KL, do Carmo AM. Detection of vertical root fractures in the presence of intracanal metallic post: a comparison between periapical radiography and cone-beam computed tomography. *J Endod.* 2013;39(12):1620-4. [[Crossref](#)] [[PubMed](#)]

10. Chang E, Lam E, Shah P, Azarpazhooh A. Cone-beam Computed Tomography for Detecting Vertical Root Fractures in Endodontically Treated Teeth: A Systematic Review. *J Endod.* 2016;42(2):177-85. [[Crossref](#)] [[PubMed](#)]
11. Edlund M, Nair MK, Nair UP. Detection of vertical root fractures by using cone-beam computed tomography: a clinical study. *J Endod.* 2011;37(6):768-72. [[Crossref](#)] [[PubMed](#)]
12. Neves FS, Freitas DQ, Campos PS, Ekestubbe A, Lofthag-Hansen S. Evaluation of cone-beam computed tomography in the diagnosis of vertical root fractures: the influence of imaging modes and root canal materials. *J Endod.* 2014;40(10):1530-6. [[Crossref](#)] [[PubMed](#)]
13. Landis JR, Koch GG. The measurement of observer agreement for categorical data. *Biometrics.* 1977;33(1):159-74. [[Crossref](#)] [[PubMed](#)]
14. Ezzodini Ardakani F, Razavi SH, Tabrizzadeh M. Diagnostic value of cone-beam computed tomography and periapical radiography in detection of vertical root fracture. *Iran Endod J.* 2015;10(2):122-6. [[PubMed](#)] [[PMC](#)]
15. Valizadeh S, Khosravi M, Azizi Z. Diagnostic accuracy of conventional, digital and Cone Beam CT in vertical root fracture detection. *IEJ Iranian Endodontic Journal* 2011;6(1):15-20. [[Link](#)]
16. Varshosaz M, Tavakoli MA, Mostafavi M, Baghban AA. Comparison of conventional radiography with cone beam computed tomography for detection of vertical root fractures: an in vitro study. *J Oral Sci.* 2010;52(4):593-7. [[Crossref](#)] [[PubMed](#)]
17. Wenzel A, Haitei-Neto F, Frydenberg M, Kirkevang LL. Variable-resolution cone-beam computerized tomography with enhancement filtration compared with intraoral photostimulable phosphor radiography in detection of transverse root fractures in an in vitro model. *Oral Surg Oral Med Oral Pathol Oral Radiol Endod.* 2009;108(6):939-45. [[Crossref](#)] [[PubMed](#)]
18. Wenzel A, Kirkevang LL. High resolution charge-coupled device sensor vs. medium resolution photostimulable phosphor plate digital receptors for detection of root fractures in vitro. *Dent Traumatol.* 2005;21(1):32-6. [[Crossref](#)] [[PubMed](#)]
19. De Martin E Silva D, Campos CN, Pires Carvalho AC, Devito KL. Diagnosis of mesiodistal vertical root fractures in teeth with metal posts: influence of applying filters in cone-beam computed tomography images at different resolutions. *J Endod.* 2018;44(3):470-4. [[Crossref](#)] [[PubMed](#)]
20. Sogur E, Baksi BG, Mert A. The effect of delayed scanning of storage phosphor plates on occlusal caries detection. *Dentomaxillofac Radiol.* 2012;41(4):309-15. [[Crossref](#)] [[PubMed](#)] [[PMC](#)]